

Ultrasound Guided Platelets Rich Plasma Injection as Pain Management Method for Knee Pain in Partial Medial Collateral Ligament Injury

Hayder Ghali Algawwam

Consultatory Clinic for Chest & Pulmonary Diseases/ NTP || North Region || Iraq

Huda Ihsan KhairuAllah

Abdullah Ahmed Mohammad

Nuha Abdulwahab Muhammed Ali

Azadi Teaching Hospital || Kirkuk || Iraq

Abstract: Objective: the aim of this study is to evaluate effectiveness of ultrasound guided platelets rich plasma (PRP) injection as pain management method in patients complaining from partial injury of medial collateral ligament
Patients and Methods: a retrospective study conducted for the period from January 1, 2017 until July 31, 2019, 31 patients (21 females and 10 males) visited Dr Abdullah Ahmed Mohammad private clinic in Kirkuk, Iraq because of knee pain as a result of partial tear of medial collateral ligament, they received ultrasound guided PRP injections. The PRP was obtained by centrifugation of patient's own blood. The degree of response to treatment grading was as following: excellent, good, fair and poor.

Results: the mean age was 52 ± 1.5 years, Two-thirds of patients were female and one-third were male, (n: 27, 87.0%) of patients received one sessions, excellent or good response to treatment found in most of patients (n: 28,90.3 %) while only three patients (9.7%) didn't respond to treatment, there was a significant statistical difference between the 2 groups ($p < 0.01$)

Conclusion: ultrasound guided PRP injection appears effective and improved clinical outcome in knee pain in MCL partial tear

Keywords: Platelets Rich Plasma, Pain Management, Medial Collateral Ligament Tear.

حقن البلازما الغنية بالصفائح الدموية الموجهة بالموجات فوق الصوتية كطريقة للتحكم في الألم في آلام الركبة في إصابة الرباط الجانبي الإنسي الجزئي

حيدر غالي الكوادم

العيادة الاستشارية للأمراض الصدرية والتنفسية || البرنامج الوطني لمكافحة التدخين || العراق

هدى إحسان خير الله

عبد الله أحمد محمد

نهى عبد الوهاب محمد علي

مستشفى آزادي التعليمي || كركوك || العراق

الملخص: هدفت الدراسة إلى لتقييم فعالية حقن الرباط الجانبي الأنسي بدلالة السونار بالبلازما الغنية بالصفائح الدموية كطريقة لمعالجة آلام الركبة.

طريقة البحث: دراسة اعتيادية أجريت على مدى سنتين ونصف (1 كانون ثاني 2017 - 31 تموز 2019)، 31 مريضاً (21 إناث و10 ذكور) راجعوا العيادة الخاصة للباحث الثالث الدكتور عبد الله أحمد محمد في محافظة كركوك، العراق بسبب شكاوهم من آلام الركبة، تم حقن الرباط الجانبي الأنسي للركبة بدلالة السونار بالبلازما الغنية بالصفائح الدموية التي تم تحضيرها بواسطة الطرد المركزي للدم المسحوب من نفس المريض. الاستجابة للعلاج صنفت إلى ممتاز، جيد، مقبول وضعيف.

النتائج: معدل العمر كان $52 \pm 1,5$ سنة. معظم المرضى (عدد 27، 87%) تلقوا حقن لمرة واحدة، معظم المرضى (عدد 28، 90,3%) أظهروا أما استجابة جيدة أو ممتازة للعلاج، بينما ثلاثة مرضى فقط (9,7%) أظهروا إما استجابة مقبولة أو ضعيفة وكان هناك فرق ذو دلالة إحصائية معنوية بين المجموعتين.

الاستنتاج: حقن الرباط الجانبي الأنسي بالبلازما الغنية بالصفائح الدموية بدلالة السونار يبدو أنه طريقة فعالة، آمنة ورخيصة لمعالجة آلام الركبة الناتجة من التمزق الجزئي للرباط المذكور.

الكلمات المفتاحية: البلازما الغنية بالصفائح الدموية، إدارة الألم، تمزق الرباط الجانبي الأنسي.

Introduction:

Medial collateral ligament (MCL), it is also called the tibial collateral ligament is the principal backing structure of the medial side of the knee. MCL is part of the medial capsuloligamentous complex and it is made up of three layers; layer 1 is the superficial layer, consisting of the deep fascia from the continuity of the fascia overlying the vastus medialis anteriorly and the sartorius posteriorly, layer 2 is the intermediate layer, which is the superficial portion of the MCL, it is a strong, flat, and straight vertical fibrous band in the middle third of the knee with one proximal femoral attachment and two distal tibial attachments and layer 3 which is the deep layer and it is a thickening of the medial joint capsule (1).

It is so vital to have a wide information for all the parts involved in the MCL for prevention of trauma, treatment and rehabilitation that's because MCL is a common potential place of injury in sporters. MCL injury is more public in contact sports especially in males. The MCL is attached to the medial meniscus and capsule, it is a strong ligament and a static stabilizer of the knee (2).

Injuries in medial collateral ligament is the furthestmost communal injuries in knee ligaments caused by valgus stress. MCL injury are categorized into three degrees of severity; grade I, tenderness over the medial aspect of knee with normal joint stability, grade II, tenderness over the medial aspect of the knee with valgus instability at 25 to 30 degrees of flexion and grade III, complete distraction of the ligament with full instability in full extension (3).

MCL is the biggest component found on the medial aspect of the knee joint, its length is 8 to 10 cm and it is considered as one of four main ligaments which support the knee joint. The MCL is important for providing support in valgus stress position, rotational forces position, and anterior translational forces on the tibia. MCL injuries considered the most common ligamentous injury of the knee because the lateral aspect of the knee is usually the most exposed during sport. The patient frequently describes a feeling of the knee "giving out" at the time of injury followed by a rapid filling of the joint with blood, which

becomes acutely painful. Pain on examination is typically worse over the course of the MCL and most often near its proximal insertion end (4).

Ultrasound (US) examination and evaluation can give examiner a good imaging modality. For diagnostic US, relative recent advances in technology have improved ultrasound's ability to diagnose a myriad of musculoskeletal problems with enhanced resolution. The structures most imaged by linear probe with good resolution, which gives good visualization of tendon, muscle, nerve, joint, and some osseous pathology (5).

On ultrasound, injured MCL structures will look as thick and heterogeneous hypoechoic, while the normal MCL appear as a thin and homogeneous hypoechoic band with 4.3 mm average thickness of 4.3 mm at the femoral attachment and of 2.3 mm at the tibial attachment (6).

Examination with ultrasound gaudiness permit excellent assessment and estimation of the tears. Ultrasound guided interferences will span the surgical management and expand patient's quality of life in those unfit for surgical interventions (7). Ultrasound have a relatively low cost and dynamic scanning which are the main benefits of US over magnetic resonance imaging (MRI), also US guided procedure of the MCL and its related problems is a very good diagnostic technique (1).

Treatment of high grade acute MCL lesions of the knee with PRP is a promising therapeutic option to be further explored with good quality Randomized Controlled Trials (8).

Platelets rich plasma is a component of plasma characterized by high levels of growth factors. Isolation of PRP from autologous blood could be valuable as a source of anabolic growth factors for stimulation of chondrocytes regeneration to reestablish cartilaginous tissues in knee joint (9).

PRP has been recognized as a biological treatment that could be effective in fast healing and regeneration of musculoskeletal tissue because of its inherently high concentrations of beneficial growth factors (10). PRP meaningfully increased the stretchable force of the ligament in the patients treated after 3 and 6 weeks from onset of injury (11).

The aim of this study is to evaluate the effectiveness of ultrasound guided injection with PRP which is more specific, accurate and safer than blind injection as a pain management method in knee pain as a result of the medial collateral ligament tear.

Patients and Methods

This is a reviewing and retrospective study of a group of patients with medial collateral ligament tears of knee joint. They were managed by PRP injection in the Medical Center for Family Medicine and Pain Management led by Dr Abdullah Ahmed Mohammad. Over (30) month period (January 1, 2017–July 31, 2019), 31 patients (21 females and 10 males) received medial collateral ligament PRP injection. A detailed history was taken according to a questionnaire and a complete physical and ultrasound

examination was done. The clinical notes were reviewed to determine the improvement of clinical signs and symptoms and hence the response of patients to PRP therapy.

PRP preparation done from autologous blood drawn from the patient's own vein with a 20-ml syringe. The withdrawn patient's own blood was then putted in aseptic tubes, each tube filled with 9 ml blood and 1 ml of an anticoagulant 3.8% sodium citrate. The tubes were then placed in a centrifuge at 1500 round per minute (rpm) for 10 minutes separating the sample into three parts; the upper part made of plasma, the middle part (puffy coat) made of white blood cells (WBCs) while the lower part made of red blood corpuscles (RBCs). The upper two thirds of plasma were then discarded while the lower third was transferred to another tube and placed in a centrifuge again. After 15 min of centrifugation at 3000 rpm, the upper half of the sample was discarded while the lower half would form the PRP.

Patients lie on his back, a real-time ultrasonography was done utilizing LOGIC P6 Ultrasound Machine with ML6-15 linear transducer (GE Healthcare, USA) for the medial aspect of the knee.

Patients received either 1 or 2 doses of PRP under ultrasound guidance. All injections were done aseptically using 30-G needles. the skin was injected with 1/2 cc of lidocaine & 2 cc of PRP at site of lesion.

In this study, follow up of patients continued for six months after the last injection session. The authors utilized a patient's symptoms-based questionnaire to evaluate the results after ultrasound guided PRP therapy. The questionnaire was resembling to that one designated by Bhattacharya et al. in their study paper of thoracic outlet compression but slightly modified. The questionnaire designed for patients to grade and categorize their observation of symptomatic relief using the words (Excellent) for complete relief of symptoms, (Good) for relief of most major symptoms, (Fair) for relief of some symptoms, but persistence of others and (Poor) for no improvement (12).

Inclusion criteria

Patients age 18 years and older with MCL tear.

Exclusion criteria

Exclusion criteria included: medical history of bleeding tendency and patients on anticoagulants.

Body mass index (BMI) of the patients was calculated by the equation: Weight in kilogram/ (Height in meter)² and accordingly, the patients were classified as having a healthy body weight (18.5-24.9), overweight (25-29.9), obesity I (30-34.9), obesity II (35-39.9) and obesity III (≥ 40) (13).

All the data were recorded in Microsoft Excel 2010, the data were analyzed by using of computer SPSS 11 program and the www.socscistatistics.com, the differences were considered significant when the probability (P) was less than 0.01 ($p < 0.01$) by using z test for 2 population proportions.

Results

There were 31 patients (n:21, 67.7% females and n:10, 32.3% males) with a female: male ratio of 2.1:1, Figure 1 displays the sex distribution of the studied patients.

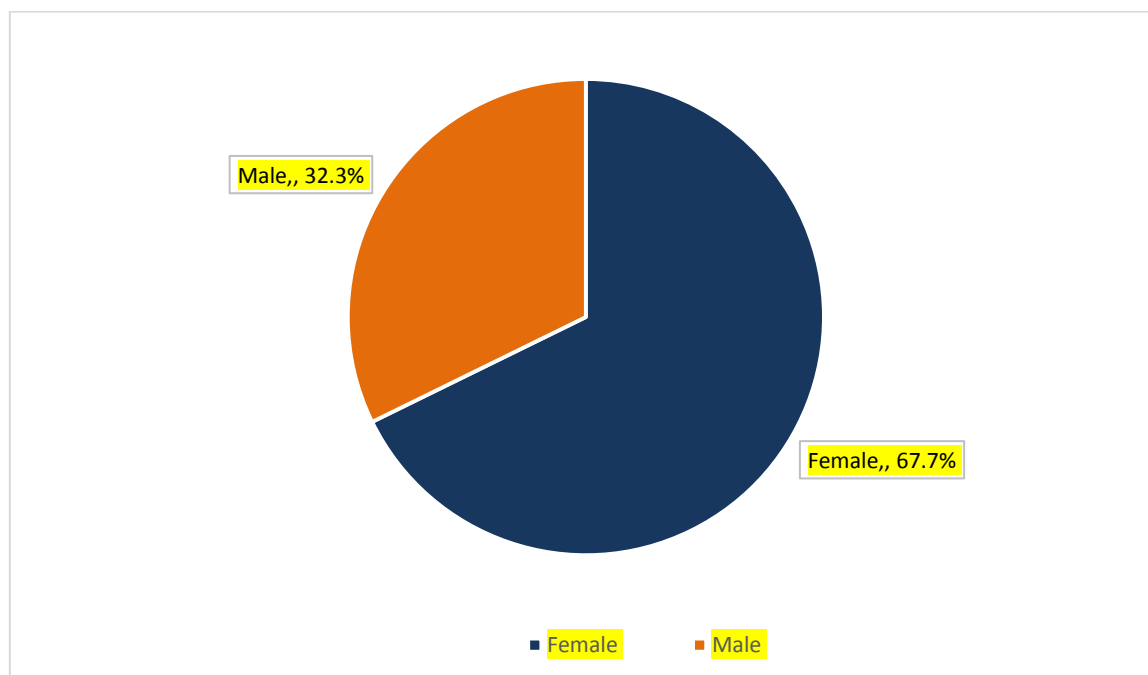


Figure (1) Patients Sex Distribution.

The age ranged between 23 and 78 years with a mean of 52.7 ± 1.5 years Figure 2 displays the age distribution of the studied patients.

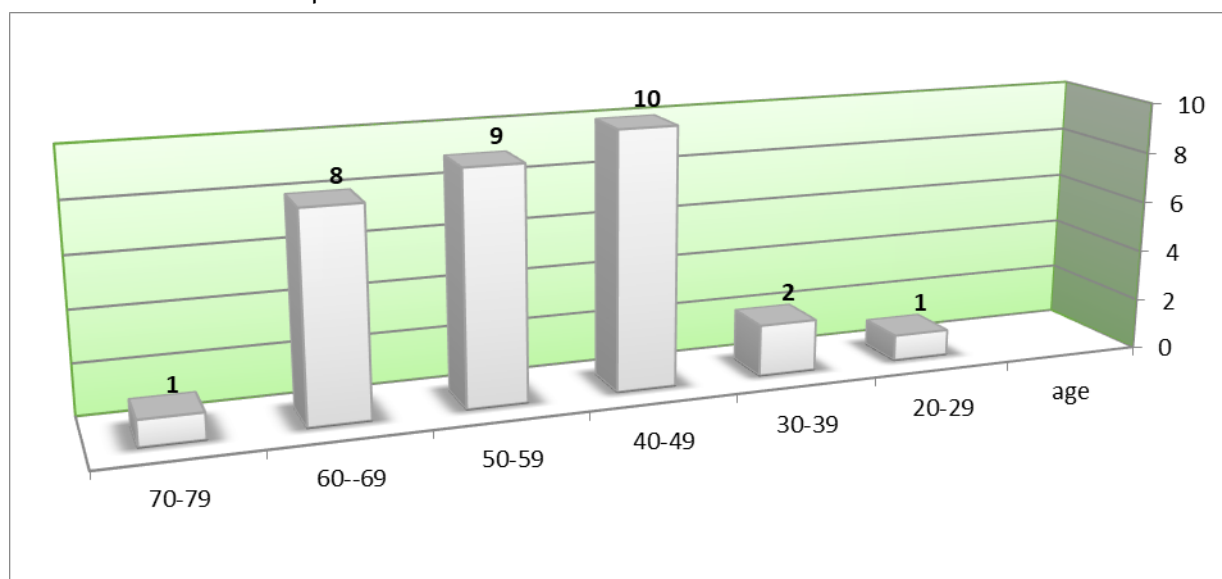


Figure (2) Patients Age Distribution.

Most of the patients were overweight or obese (n:26, 83.8%) while the patients with normal healthy weight were (n: 5, 16.12%) as shown in Figure 3.

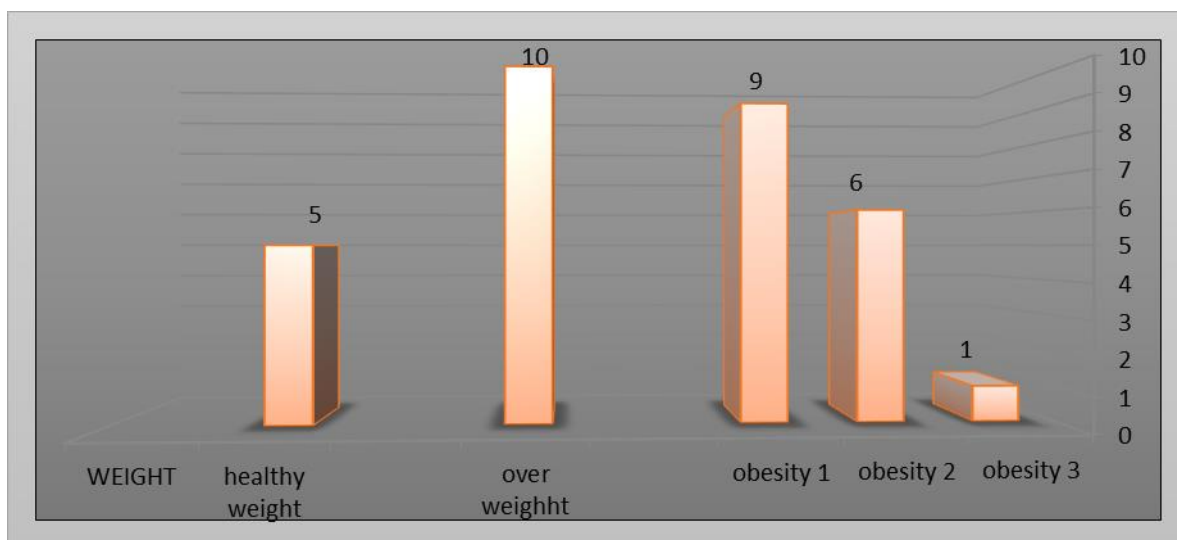


Figure (3) Patients BMI distribution.

Table (1) shows the co-morbidities encountered in the studied patients.

Co-morbidity	Sex		Total
	Male	Female	
Overweight or Obesity	7	19	26
Hypertension	1	4	5
Diabetes Mellitus & Hypertension	2	2	4
Diabetes Mellitus	1	1	2

The top co-morbid condition was overweight and obesity as most of the patients (n: 26, 83.9%) were either overweight or obese. Hypertension either alone or in combination with diabetes mellitus ranked second (n: 9, 29%), while six patients (19.4%) had diabetes mellitus either alone or in combination with hypertension as shown in Table 1.

The housewives were (n:13, 42%), governmental employee (n:11, 35.5%), free workers (n: 5, 16%) and retired patients was (n: 2, 6.5%) as shown in Figure 4.

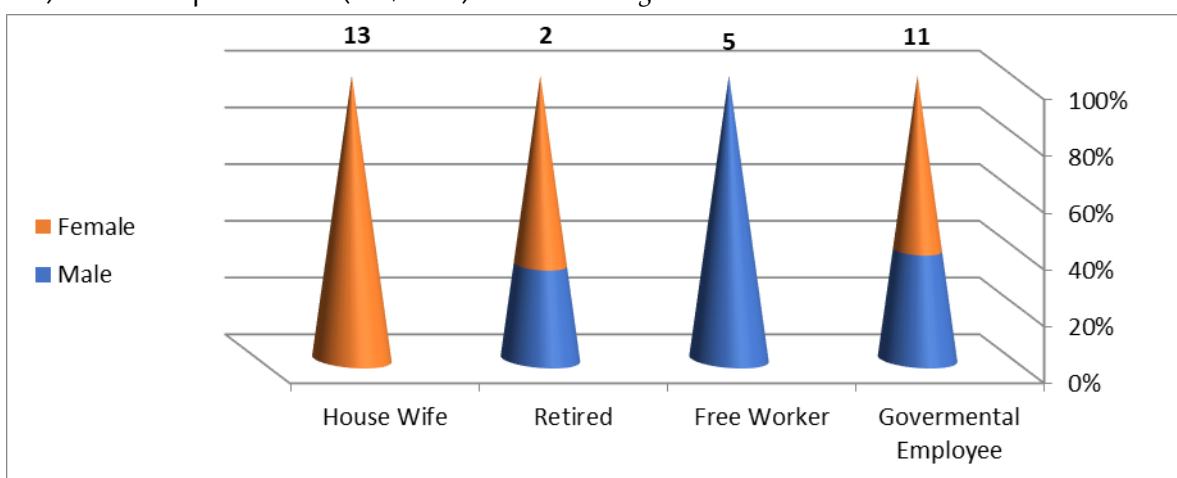


Figure (4) Patients Job Distribution

Figure 5 shows that (n: 27, 87.1%) from patients received one session while (n: 4, 12.9%) received two session of PRP injections.

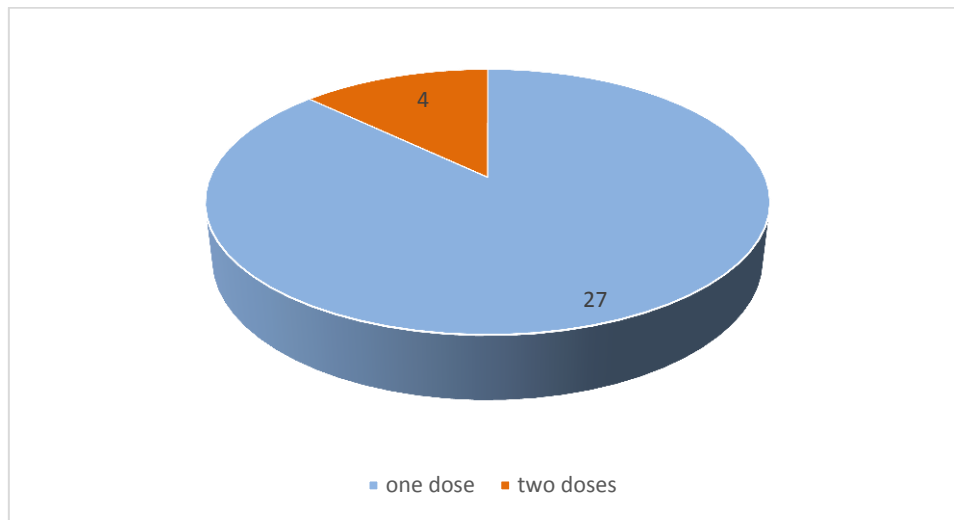


Figure (5) Distribution of patients treated with one or two sessions of PRP injections.

As shown Figure 6 (n:28, 90.3%) from patients had either excellent or good response to treatment, while (n:3, 9.7%) from patient had either fair or poor response to treatment, there was a significant statistical difference between the 2 groups ($p < 0.01$).

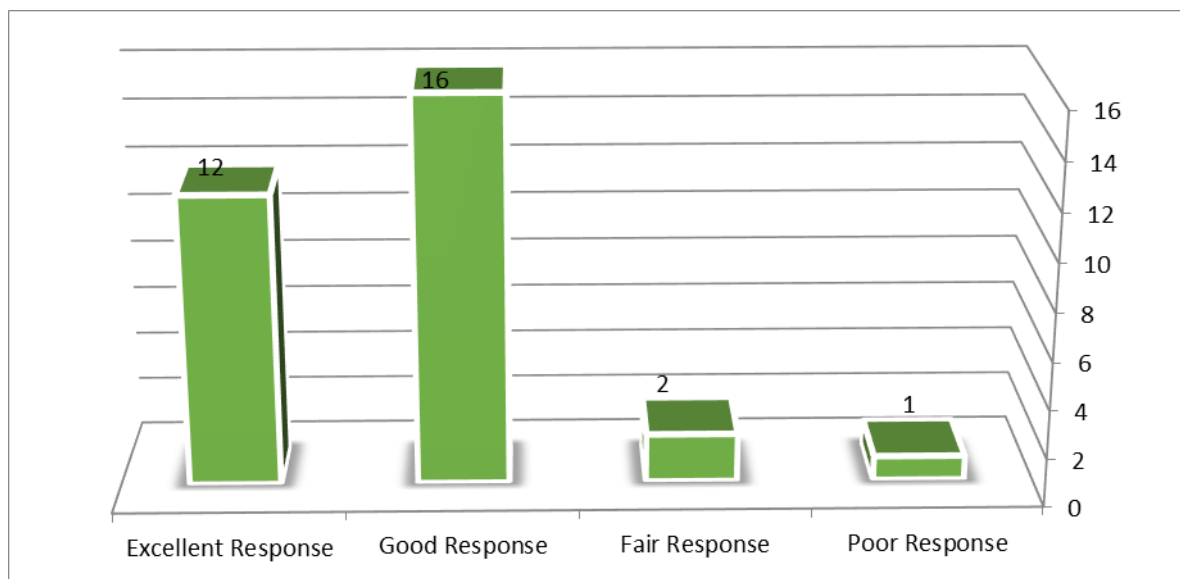


Figure (6) Distribution of patients according to response to treatment.

Discussion

PRP is a biological agent which gained its attractiveness as an adjuvant treatment for musculoskeletal injuries especially in family medicine and sports medicine as a safe and cheap natural physiological method. It is a fractionated volume of plasma of the own patient's blood which contains a platelet concentrate. The tissue rebuilding properties of PRP is attributed in part to its growth factors

including Platelet Derived Growth Factor, Transforming Growth Factor- β 1, Insulin- Like Growth Factor, and Vascular Endothelial Growth Factor. These growth factors are associated with repair processes of the central nervous system (14), while treatment with steroids, in the situation of abnormal injured tendon, is not recommended because of the possible risk of rupture from inadvertent intra tendinous injection (7).

The need and indication using ultrasound guided injections in musculoskeletal injuries has increased in last years as physicians and patients pursue confirmation of needle position, injections in musculoskeletal injuries are commonly delivered blindly just by utilizing clinical skills and experiences of physicians in detection of lesion sites according to patient's complain, examination and anatomical landmarks, so ultrasound guided interventions developed as the favored way for many doctors and patients. Rehabilitation may be needed to support musculoskeletal injuries treatment methods for pain relief (14).

In our study most of patients were between 40-69 years old and about 2/3 of the patients were female and 1/3 male while many papers published before shows there is no statistical significant difference in MCL strain between genders for similar circumstances and MCL injuries are more common in younger age group (15, 16, 17). On the other hand, some studies have found that women, especially high school age, are more likely to sustain an MCL injury (19) Other studies have found that college age men are more likely to sustain an MCL injury and many experts believe MCL injuries occur equally in both men and women (19)

Many factors explain the differences in epidemiology results between our study and previous studies about MCL. Socioeconomic status, job of patients, comorbidities association including obesity, activity and exercise and also specialty of clinic visited by patients complaining from knee pain, is it family medicine practice as in case of our study, orthopedic practice or sport medicine clinic. In our opinion; all the above-mentioned factors could be the reason behind these differences.

In this study, 19 patients out of 24 (79.1%) were female housewives and governmental employee in which there were moving most of the day and more prone to injury, while in study published in 2019 shows that MCL injury is the most popular knee trauma in football players in which 75% of the MCL injuries occurred with a contact mechanism (20).

In our study 27 patients (87.0%) received only one session of ultrasound guided PRP injections, this is in concordance to a study done in Taleghani Hospital in Tehran, which stated also that single injection of PRP had statistical significant pain decrease which assist in faster rehabilitation progress, shorter time spent out of play and less time without exercise which is vital to professional athletes (21).

In our study 28 patients (90.3 %) had either excellent or good response to treatment, PRP for MCL tear is also based on many studies that support usage of growth factors that enhancing collagen regeneration and tissue healing. Early studies of PRP on animal MCL showed very good and fast healing process in the early stages of an acute injury (22).

In summary, MCL injury of knee are still major problems in sports medicine and general population, ultrasound guided PRP injection appears an effective, safe and cheap pain management method improving clinical outcome in chronic knee pain in MCL partial tear.

References

- 1- Tony Y. Li, RDMS, RVT, RMSK, CRGS, CRVS (2017). Distension of the Medial Collateral Ligament Bursa of the Knee with Possible Bursitis: A Sonographic Case Series. *Journal of Diagnostic Medical Sonography*. 33(1): 22-30.
- 2- Luis Pedro Duarte Silva, C. Desai, N. Loureiro, H. Pereira, and J. Espregueira-Mendes (2015). Knee Medial Collateral Ligament Injuries, *Football Traumatology: New Trends*, DOI 10.1007/978-3-319-18245-2_14.2nd. Edition P; 126-132.
- 3- Guoyou Zou, Minqian Zheng, Wang Chen, Xiao He and Dingwei Cang (2020). Autologous platelet-rich plasma therapy for refractory pain after low-grade medial collateral ligament injury: *Journal of International Medical Research* 48(2): 1–7.
- 4- Kyle Andrews^a, Alex Lub, Lucas Mckean^b, Nabil Ebraheima. (2017). Review: Medial collateral ligament injuries: *Journal of Orthopaedics*. 14: 550–554.
- 5- Paul H. Lento and Scott Primack. (2008). Advances and utility of diagnostic ultrasound in musculoskeletal medicine. *Curr Rev Musculoskelet Med*. 1(1): 24–31.
- 6- J I Lee, I S Song, Y B Jung, Y G Kim, C H Wang, H Yu, Y S Kim, K S Kim, T L Pope Jr. (1996). Medial collateral ligament injuries of the knee: ultrasonographic findings: *J Ultrasound Med*. 15(9): 621-5.
- 7- J. Davidson and S. Jayaraman. (2011). Guided interventions in musculoskeletal ultrasound: what's the evidence. *Clinical Radiology*. 66 140e152.
- 8- Cristiano Eirale, Eduardo Mauri and Bruce Hamilton. (2012). Use of Platelet Rich Plasma in an Isolated Complete Medial Collateral Ligament Lesion in a Professional Football (Soccer) Player: A Case Report. *Asian J Sports Med*. 4(2): 158–162.
- 9- Abdullah Ahmed Mohammad and Hayder Ghali Wadi Algawwam. (2019). Efficacy of intra-articular injection of activated platelet rich plasma as pain management method in chronic knee pain. *Iraq Med J*. 2(4): 106–110.
- 10- Robert F. La Prade, yz, Laurie R. Goodrich, Jennifer Phillips and Grant J. (2017). Use of Platelet-Rich Plasma Immediately After an Injury Did Not Improve Ligament Healing, and Increasing Platelet Concentrations Was Detrimental in an in Vivo Animal Model. *The American Journal of Sports Medicine*. 46(3):702-712.
- 11- Eduardo Louzada da Costa, Luiz Eduardo Moreira Teixeira, Bruno Jannotti Pádua, Ivana Duval de Araújo, Leonardo de Souza Vasconcellos and Luide Scalioni Borges Dias (2017). Biomechanical study

- of the effect of platelet rich plasma on the treatment of medial collateral ligament lesion in rabbits. *Acta Cir Bras.* 32(10): 827-835.
- 12- Bhattacharya V, Hansrani M, Wyatt MG, Lambert D and Jones DN. (2003). Outcome following surgery for thoracic outlet syndrome. *Eur J Vasc Endovasc Surg.* 26:170–175.
- 13- Zelman DC; Dukes E; Brandenburg N; Bostrom A and Gore M. (2005). Identification of cut-points for mild, moderate and severe pain due to diabetic peripheral neuropathy. *Pain.* 115: 29–36.
- 14- Abdullah Ahmed Mohammad and Hayder Ghali Wadi Algawwam. (2019) Para-vertebral intramuscular platelet rich plasma vs. subcutaneous ozone injection for chronic low back pain: Iraq *Med J.* 3(2); 47–51.
- 15- Nathan D. Schilaty, Nathaniel A. Bates, Christopher V. Nagelli, Aaron J. Krych and Timothy E. (2018). Sex-Based Differences of Medial Collateral Ligament and Anterior Cruciate Ligament Strains with Cadaveric Impact Simulations. *The Orthopaedic Journal of Sports Medicine.* 6(4):12: 4.8.
- 16- Christopher J. Roach, Chad A. Haley, Kenneth L. Cameron, Mark Pallis, Steven J. Svoboda and Brett D. Owens. (2012). The Epidemiology of Medial Collateral Ligament Sprains in Young Athletes. *The American Journal of Sports Medicine.* 42(5): 1103-1109.
- 17- Robert F. Laprade and Coen A. Wijdicks. (2012). The Management of Injuries to the Medial Side of the Knee. *J Orthop Sports Phys Ther.* 42(3):221-33.
- 18- Stanley LE, Kerr ZY, Dompier TP, and Padua DA. (2016). Sex differences in the incidence of anterior cruciate ligament, medial collateral ligament, and meniscal injuries in collegiate and high school sports: 2009-2010 through 2013-2014. *Am J Sports Med.*:0363546516630927. doi:10.1177/0363546516630927.
- 19- Bollen S. (2000). Epidemiology of knee injuries: diagnosis and triage. *Br J Sports Med.* 34(3): 227-8
- 20- Matilda Lundblad, Martin Hägglund, Christoffer Thomeé, Eric Hamrin Senorski, Jan Ekstrand and Jon Karlsson. (2019). Medial collateral ligament injuries of the knee in male professional football players: a prospective three-season study of 130 cases from the UEFA Elite Club Injury Study. *Knee Surgery Sports Traumatology Arthroscopy.* 27 (11): 1-7.
- 21- Farzad Sharaki, Mehrshad Poursaeid Esfahani, Mohammadreza Minator Sajjadi, Shahin Salehi Amir, Hossein Abedi Yekta, Mohammad Hassabi. (2019). Determination of Effect of Platelet Rich Plasma Injection on Improving Pain and Function in Young Healthy Athletes with Isolated Grade 2 or 3 Knee Medial Collateral Ligament Sprains. *Novelty in Biomedicine.* 3:147-57.
- 22- Cameron Kia, Joshua Baldino, Ryan Bell, Alim Ramji, Colin Uyeki, Augustus Mazzocca. (2018). Platelet-Rich Plasma: Review of Current Literature on its Use for Tendon and Ligament Pathology. *Curr Rev Musculoskelet Med.* 11:566–572.